

BELL'S PALSY  


---

AND  


---

THE UPPER  


---

CERVICAL SPINE

Robert Kessinger, DC  
Dessislava Boneva, DC, FKCS  
Kessinger Specific Chiropractic Clinic  
Cape Girardeau, MO

Submitted August 12, 1999  
In revised form September 16, 1999

### ABSTRACT

*Objective:* This case study documents the outcome of two patients presenting with Bell's palsy and receiving upper cervical specific chiropractic care and suggests a pathophysiological mechanism that correlates response to upper cervical reduction of subluxation with attenuation and recovery from symptoms.

*Clinical Features:* The first patient was a 39-year-old truck driver who presented with Bell's palsy of two weeks duration. The right side of his face was paralyzed and he was unable to close his right eye. No perceptible movement was detected upon close examination. He had received a manipulative procedure from a neurologist one day following onset with no improvement. Initial x-ray analysis and skin temperature differential analysis revealed an upper cervical subluxation.

The second patient was a 16-year-old female admitted for upper cervical chiropractic care one day following the onset of Bell's palsy. She presented with facial paralysis on the right and was unable to close her right eye. Only barely perceptible movement was observed around her right eye. Initial x-ray analysis and skin temperature differential analysis revealed an upper cervical subluxation.

*Intervention and Outcome:* Both patients received upper cervical specific care consisting of specific adjustments to the upper cervical spine using a knee chest solid head piece table "navigated" by x-ray analysis and paraspinal skin temperature differential analysis. The first patient began care as a Grade VI on the House-Brackmann facial nerve classification system and returned to Grade I normal following the course of care. The second patient began care as a Grade V and returned to a Grade I normal.

*Conclusion:* The clinical progress that was documented in these two patients suggests a connection between correction of the upper cervical subluxation and a decrease in edema and inflammation of the facial nerve and facilitation of remyelination.

**Key Words:** Bell's Palsy, Chiropractic, Upper Cervical Spine, Medulla Oblongata, Facial Nerve Paralysis.

### INTRODUCTION

Bell's palsy (BP) was named after a Scottish surgeon and physiologist for his published work on facial palsy (1). In 1821, Sir Charles Bell demonstrated the facial nerve to be a separate nerve. Nicholas A. Friedrich and Richard Powell published reports in 1798 and 1813, respectively, prior to Sir Charles Bell, but Bell's name became synonymous with the condition.

Initial symptoms of Bell's palsy usually includes pain behind the ear on the affected side, followed by facial weakness, which develops in some cases to complete paralysis within hours. Onset is between 3 to 72 hours, and 50% of patients experience pain in the mastoid process of the involved side. The affected side is expressionless, and patients may complain about the seemingly twisted intact side rather than the involved side. In the most severe cases, the palpebral fissure is wide, and the patients cannot close their eye on that side. In addition to the facial weakness there may be other accompanying signs and symptoms, such as facial or retroauricular pain, dysgeusia hyperacusis, decreased tearing, loss of sense of taste, and altered salivation (2).

The prevalence of Bell's palsy is 8 to 240 cases per 100,000 (3-5). Statistical review has shown that slightly more of the cases occur in female patients. There is an increased incidence in the fall and winter seasons (6,7). Recurrent symptoms occur in fewer than 10% of the individuals, and less than 1% of the time Bell's palsy develops bilaterally.

Even though Bell's palsy is the most common cause of peripheral facial paralysis, all other causes should first be ruled out. The diagnosis of Bell's palsy, therefore, is made by exclusion. The differential categories to be considered are trauma, vascular, neoplasm, infection, and congenital (8). The House-Brackmann facial nerve classification system, approved at the Fifth International Symposium on the Facial Nerve in Bordeaux in 1985 (Table 1), was developed to assess facial nerve paralysis (9).

The prognosis for the majority of Bell's palsy patients is very good to excellent. Within three to six months, 80% of the cases will be completely resolved. However, in a few cases, the symptoms may never completely disappear. The prognosis is considered less favorable for long-term recovery for those patients not returning to normal within six months. The prognosis appears better for patients who have incomplete paralysis, i.e.,

TABLE 1.  
House-Brackmann facial nerve classification system

Grade I	Normal function	Normal facial function in all areas
Grade II	Mild dysfunction	Gross: slight weakness noticeable on close inspection; may have very slight synkinesis At rest: normal symmetry and tone Motion Forehead: moderate to good function Eye: complete closure with minimum effort Mouth: slight asymmetry
Grade III	Moderate dysfunction	Gross: obvious but not disfiguring difference between two sides; noticeable but not severe synkinesis, contractures and/or hemifacial spasm At rest: normal symmetry and tone Motion Forehead: slight to moderate movement Eye: complete closure with effort Mouth: slightly weak with maximum effort
Grade IV	Moderately severe dysfunction	Gross: obvious weakness and/or disfiguring asymmetry At rest: normal symmetry and tone Motion Forehead: none Eye: incomplete closure Mouth: asymmetry with maximum effort
Grade V	Severe dysfunction	Gross: only barely perceptible motion At rest: asymmetry Motion Forehead: none Eye: incomplete closure Mouth: slight movement
Grade VI	Total paralysis	No movement

From Shrode LW. Treatment of facial muscles affected by Bell's palsy with high-voltage electrical muscle stimulation. *J Manipulative Physiol Ther* 1993;16(5):347-52. Reprinted with permission.

are able to close their eyes, demonstrate a slow progression, are a younger age, or have normal salivary flow. Risk factors for incomplete recovery are age 55 years or older, hypertension, complete facial weakness, pain other than ear pain, and changes in tearing (1).

Electroneurography (ENoG), nerve conduction velocity, needle EMG, and submandibular gland scintigraphy are useful in prognostication of Bell's palsy in the early stages. ENoG measures the degree of degeneration of the facial nerve. In a study involving 164 cases electroneurography demonstrated that a satisfactory recovery can be expected when ENoG reveals less than 90% loss. However, when ENoG loss was greater than 90%, neither surgical decompression nor steroid therapy could change the prognosis statistically (10). Some clinicians prefer to use needle EMG instead of ENoG because of its ability to reliably reflect the degree of denervation present (11). Nerve conduction velocity is considered useful as it has shown good correlation with the ENoG in cases where ENoG reveals 60% or more

degeneration (12). Submandibular gland scintigraphy (13) is a unique method where time-activity curves are plotted to measure salivary flows following the stimulation of the submandibular gland. Submandibular gland scintigraphy can serve as a reliable indicator to predict the prognosis of acute peripheral facial nerve paralysis in its early symptomatic period.

Serial gadolinium-enhanced MRI (14) reveals a contrast enhancement of the facial nerve in a majority of cases and correlates well to the clinical presentation. However, it has not been shown to be a prognostic indicator.

Corticosteroid treatment has been recommended in standard medical textbooks (*Cecil's Textbook of Medicine*, 17th edition, 1985, *Oxford Textbook of Medicine*, 3rd edition, 1996); however, some studies have refuted the effectiveness of such intervention. Shafshak et al (15) found in a nonrandomized study that corticosteroids were effective if used within 24 hours of onset and less effective thereafter. Little difference was noted between groups receiving no care and groups receiving corticosteroid treatment

after the second day. Surgical decompression of the facial nerve in the internal auditory canal has been performed with some success in a few cases (16).

There is a small, but growing, body of published works (9,17-20) to support the many testimonial accounts and anecdotal remarks made on the effectiveness chiropractic care for patients with Bell's palsy. Palmieri and Shrode reported a relationship between autonomic communicating branches in the upper cervical spine and the facial nerve. Interestingly enough, D.D. Palmer offered a mechanism for facial paralysis in 1910 (20):

"The facial nerve has its communicating branch from the sympathetic by way of the geniculate ganglion, also a branch from the cervico-facial division, by way of the great auricular nerve, which springs from the second and third cervical nerves. The sympathetic, you will remember, is connected with the spinal nerves by the ganglia of the ganglionic cord. All this, because the cervical communicating nerve being pressed upon by the displaced cervical vertebrae."

## FINDINGS

Informed consent was obtained to report these two cases.

**Case 1:** A 39-year-old man with the occupation of truck driver presented to our clinic complaining of a paralyzed right side of his face with loss of feeling. He reported that the symptoms began two weeks before admittance and described pain in the side of his neck, occiput, and jaw on the right that felt "like somebody is pulling your teeth." Immediately preceding the paralysis, he noted an intense pain for a day in his right ear and mastoid process. There were no prior incidences, and the patient related that two weeks before the episode of right-sided face paralysis, the seat in his truck broke and the tractor-trailer had been riding extremely rough. During our examination, he was unable to raise his right eyebrow, close the right eye, show his teeth, smile, whistle, or puff his cheeks, and he reported losing the sense of taste. We noted no perceptible movement upon close examination on the right side of his face, and we classified him as a Grade VI according to the rules set forth in the House-Brackmann classification system (Table 1). We observed a loss of protective sensation in the C2 and C3 dermatome patterns on the right side. Skin Temperature Differential Analysis (STDA) performed paraspinally revealed a pattern consistent with aberrant neurophysiology in the cervical spine.

This patient had seen a neurologist 13 days before his first upper cervical chiropractic office visit and one day following the onset of Bell's palsy. The neurologist performed a gross, nonspecific manipulative procedure to the cervical spine of this patient and prescribed corticosteroid medication. The patient did not fill the prescription and was not taking any other medications on his initial office visit. He denied improvement from the treatment he had received prior to upper cervical specific chiropractic care.

X-ray examination revealed an anterior and right weight

bearing of the cervical spine with a reversed cervical curvature. A three-directional or "torque" misalignment of the atlas posterior, inferior and left (PIL), was ascertained through x-ray analysis. This represents the misaligned position of the atlas in relation to the occipital condyles. Each atlas lateral mass had misaligned posterior to the occipital condyles on their respective articulations. The left lateral mass was tracking posterior along the convergence of the left condyle. The right lateral mass slid underneath the right condyle posterior in the direction of the left lateral mass convergence angle. The anterior tubercle of the atlas is the relative point of reference used in determining the superiority or inferiority of the atlas in subluxation. Because of the anatomical shapes of the condyles and their respective atlas lateral mass, when the atlas moves posterior the anterior tubercle moves in an inferior direction. As the atlas tracked posteriorly on the left condyle along its convergence angle, it was moving toward left laterality. Therefore, the atlas listing was determined to be posterior, inferior, and left (PIL).

**Case 2:** A 16-year-old female high school student was admitted to our clinic complaining of right side facial paralysis following a low-impact motor vehicle accident one and a half weeks earlier. She reported that facial pain and edema on the right side, along with pain behind the right ear, had preceded the facial paralysis by one day. She complained of pain in the right jaw and at the zygomatic arch. There was no previous history of Bell's palsy. During our examination, she was unable to raise her right eyebrow, close her right eye, show her teeth on the right side, smile, whistle, or puff her cheeks, and she also reported losing her sense of taste. We noted only barely perceptible movement around her right eye upon close examination, and we classified her as a Grade V House-Brackmann. Skin temperature differential analysis (STDA), performed paraspinally, revealed a pattern consistent with aberrant neurophysiology in the cervical spine.

X-ray analysis revealed an atlas misalignment (spinal listing) anterior superior and left laterality (ASL) and an axis misalignment anterior, right, and superior (ARS). This case illustrates a misalignment of both the atlas and axis vertebrae. Each atlas lateral mass had misaligned anterior to its respective occipital condyle. The right lateral mass was tracking anterior along the convergence of the right condyle. The left lateral mass slid off of the left condyle track anterior with left laterality. The left laterality was in the direction of the right lateral mass convergence angle.

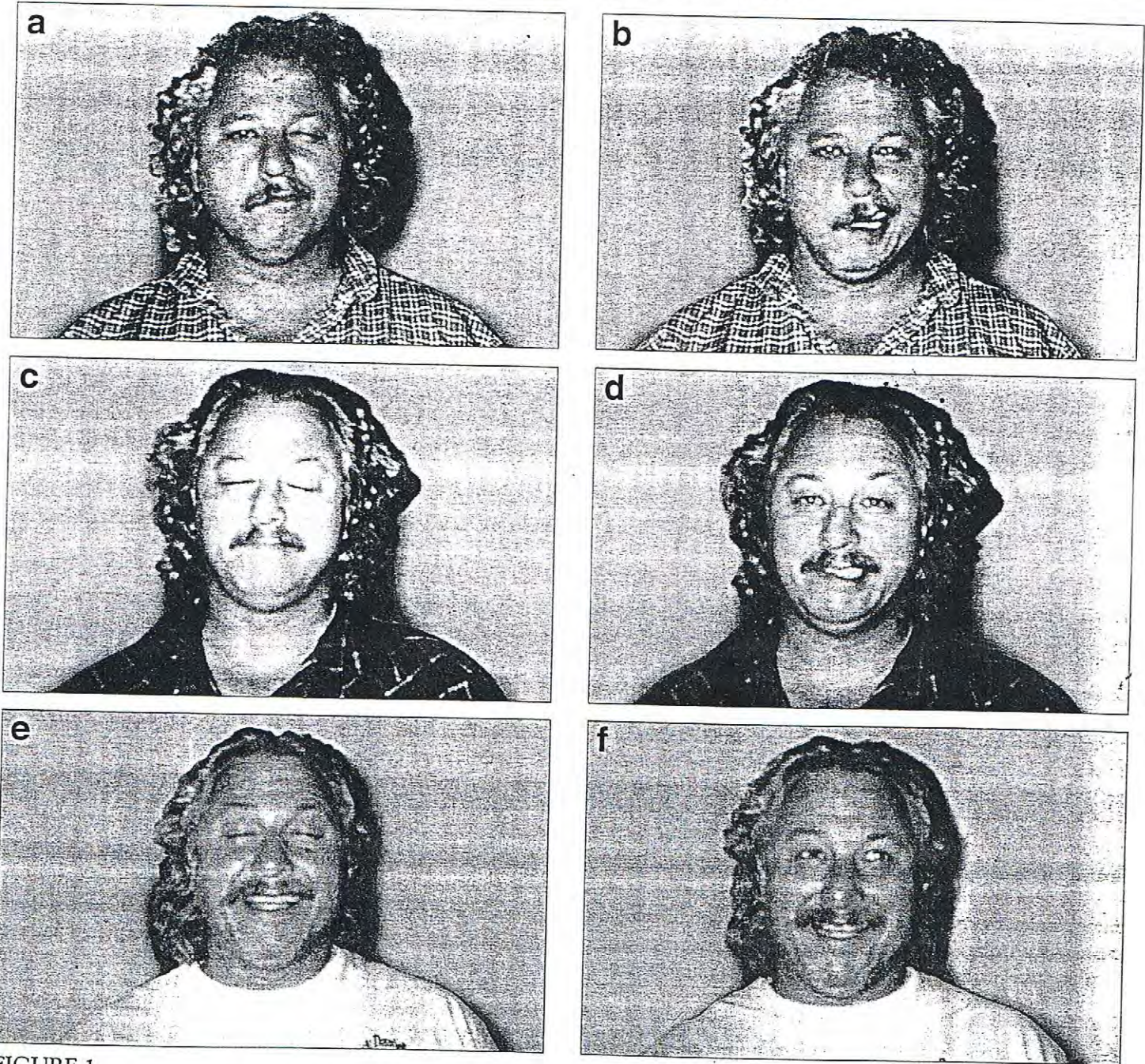As previously discussed, overall anterior movement of atlas promotes a superior anterior tubercle direction. Consequently, an atlas listing of anterior, superior, and left (ASL) was derived. The axis's inferior facet on the right side was depicted anterior and superior in relation to the right superior facet of C3. Therefore, the axis had shifted anterior and superior on the right and was considered an ARS listing. In this particular case, the atlas ASL was chosen for adjustment because it appeared to be misaligned to the greatest magnitude.

Both patients received upper cervical specific chiropractic

care consisting of upper cervical adjusting in the knee chest posture, STDA to determine the presence of vertebral subluxation in the upper cervical region, and x-ray analysis to determine the upper cervical listing.

The first patient was unable to maintain a consistent schedule because of his occupation. He had nine office visits over a period of three and a half months and received four upper cervical adjustments with the PIL atlas listing. Following the first upper cervical adjustment, he was able to close his eye, and he regained his sense of taste. Following the second upper cervical adjustment, performed two weeks after the first adjustment, he

experienced a noticeable increase in facial movement. Minimal improvements were noted for two months after these first changes occurred, and, following the fourth upper cervical adjustment two and a half months after care was initiated, the largest gains in facial movements were noted. He went from Grade VI on the House-Brackmann scale to Grade IV in two weeks, Grade III in 10 weeks, and Grade II in 14 weeks (Figure 1). This patient reported that his face was symmetrical and back to normal within eight months after of care was initiated. Thirteen months following the initiation of care, Grade I normal was established.



**FIGURE 1.**

*Case 1. Facial features before care (a, b), twelve weeks (c,d) and one year (e,f) following initiation of chiropractic care.*

The second patient had 30 office visits over three months. She received five upper cervical adjustments with the ASL atlas listing and two adjustments with the ARS axis listing. Following the first upper cervical adjustment, she reported a return of her sense of taste later the same day. We performed the second ASL atlas adjustment three days following the first ASL atlas correction. One day following the second adjustment, she was able to close her eye. Immediately following the third ASL atlas adjustment, four weeks after care was initiated, she noted a vast improvement in the function of her lower facial muscles. She went from a Grade V to Grade III in four weeks, then from a Grade III to a Grade II immediately following the third ASL atlas adjustment. Grade I was reached during the eighth week of care (Figure 2).

## DISCUSSION

### *Skin Temperature Differential Analysis*

We used a bilateral skin temperature differential analysis (STDA), performed paraspinally via a Thermoscribe II thermocouple instrument, to detect aberrant neurophysiological function in the cervical spine. The findings were interpreted as the neurological component of a vertebral subluxation (21-32). The control of thermoregulatory function is thought to be centered in the hypothalamus and refined at each spinal cord segment through spinal neuronal function (27). Skin temperatures are constantly changing as a function of the adaptation process throughout the entire body. Differences in temperature found from one side of the spine to the other that are static and persistent over time (days, weeks, or months) indicate a lack of thermal adaptation and are thought to be the result of aberrant neurophysiology.

The STDA instrument records readings on a graph display. STDA Graphs are interpreted by analyzing the similarity to a patient's previous graphs. Constant linear breaks that are significantly similar within the graph readings are identified and collectively make up the patient's specific subluxation pattern (22,23). It is presumed that each person with an upper cervical subluxation will display an asymmetrical temperature differential pattern that is unique and is considered to represent his or her subluxation pattern. Before the first upper cervical adjustment is performed, two or more graphs are recorded for establishing a static and persistent pattern to confirm the presence of an upper cervical subluxation. An STDA performed during each office visit was the criterion used to determine the presence of the upper cervical subluxation and when to administer an upper cervical adjustment.

### *Upper Cervical Knee Chest Adjustment*

The upper cervical adjustments were performed on a kneechest table with a solid headpiece (33-35). The adjustment procedure was based on the major spinal listings of PIL for the first patient and ASL for the second patient. Each patient was instructed to place the sternal notch on the front of the kneechest table while turning his or her head to the left, thereby placing

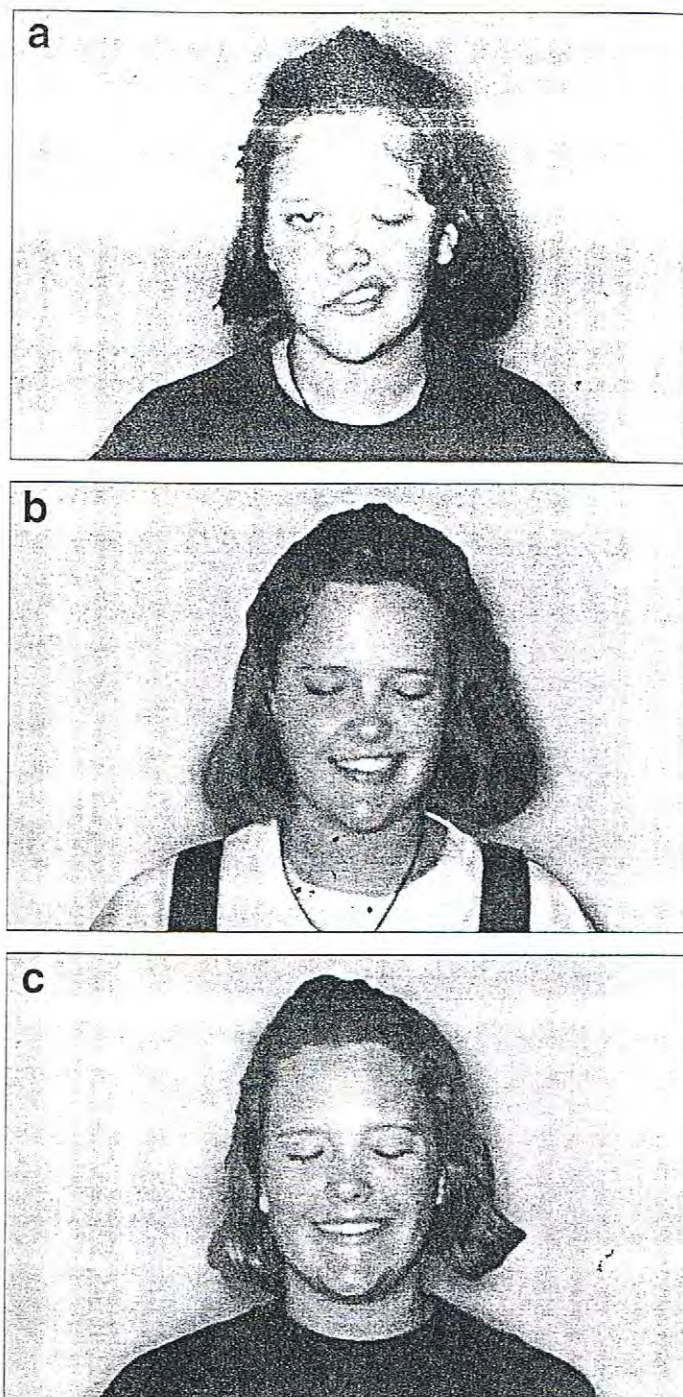


FIGURE 2.  
Case 1. Facial features prior to (a), five weeks (b), and ten weeks (c) following initiation of chiropractic care.

the right side of the head on the table. Each patient was instructed to relax, laying his or her shoulders and right side of the neck on the table. For the adjustive thrust, we made contact with the pisiform of the left hand onto the soft tissue covering the posterior arch of the atlas. A tissue pull and roll-in of the left-arched hand preceded the contact of the left posterior arch of the atlas.

For the first patient with the PIL listing, the tissue pull was accomplished with the middle digit of the right hand beginning at the posterior most portion of the posterior arch and pulling tissue in a half circle clockwise to the anterior portion of the posterior arch. For the second patient, the same procedure was followed with a counterclockwise direction of the tissue pull. The roll-in, a slight movement performed to keep the previously pulled tissue taut and to secure the contact point, was accomplished by arching the left hand in the adjusting position, and rolling the pisiform contact clockwise onto the posterior arch. Following the roll-in by the left hand, the right hand was criss-crossed over and around the left hand to produce the mechanics necessary for a torquing toggle action at the moment of the thrust. A high-velocity, low-amplitude torque and toggle thrust was administered. The adjustment does produce an audible sound, but it should not be painful when applied correctly.

The upper cervical vertebrae misalign in three different directions at the same time when in subluxation (36-46). Because each patient is structurally unique, as well as asymmetrical, in the upper cervical region, every upper cervical subluxation is unique. Therefore, the adjusting procedure in the upper cervical spine should be tailor-made for the most consistent positive outcome.

Immediately following each upper cervical adjustment, the patient was instructed to rest supine for 60 minutes in a booth on a bench with specifically tailored cervical support. The rest period is considered necessary for the surrounding soft tissue to adapt to the adjusted position of the upper cervical vertebrae and to promote a better environment for stability of the correction of the subluxation (39).

#### *Pathophysiology*

The motor nucleus of the facial nerve, superior salivatory nucleus, and solitary tract nucleus are located in the superior aspect of the medulla oblongata. The motor nucleus of the facial nerve and the superior salivatory nucleus perform the motor functions of the facial nerve, whereas the solitary tract nucleus contains the sensory portion. Fibers from all three of these nuclei enter the internal acoustic meatus and join at the geniculate ganglion. The sensory portion of the facial nerve performs the function of taste at the anterior two-thirds of the tongue via the Chorda Tympani nerve. The motor portion of the facial nerve exits the stylomastoid foramen and has five branches that supply the facial muscles from the frontal belly of the epicranium to the platysma (40) (Figure 3).

Bell's palsy is a lower motor neuron lesion with interference to the facial nerve occurring between nucleus of the facial nerve in the medulla and the periphery. An upper motor neuron lesion can occur, involving the neural pathway of the contralateral side between the cortex and the medulla via the corticobulbar tract. This lesion may appear similar to Bell's palsy without paralysis in the muscles of the forehead and around the eyes.

Bell's palsy is also known as Idiopathic Unilateral Facial Paralysis of Sudden Onset. Although the cause is considered

unknown, the histologic characteristics have been described (1,41-44). The Schwann cells undergo chromatolysis and ballooning of the nuclei, with associated edema and disruption of nerve transmission. Subsequent lymphocytic infiltration may then cause fragmentation of the myelin sheath with resultant demyelination. The peripheral axons may also be affected, leaving damaged, but potentially repairable, nerves. Provided that the distal edema and inflammation resolve, remyelination and functional muscle innervation result.

Various clinical studies have suggested an etiological link between Bell's palsy and herpes simplex virus (HSV) (1,5,41,42,45). Animal experiments have demonstrated the ability of HSV to produce Bell's palsy. In situ hybridization and the polymerase chain reaction detects HSV DNA in the geniculate ganglia of control patients, supporting the hypothetical latent state of HSV in the geniculate ganglia (45). In an 82-subject study performed by researchers at the Facial Paralysis Research Center in Oakland, California (1,5), all patients with Bell's palsy had antibodies to the herpes simplex virus and 85% of the control group with no symptoms had the antibodies. Bell's palsy has been noted to follow similar instances that are common with the activation of HSV, i.e., upper respiratory tract infections, exposure to cold drafts, ultraviolet light or sunburn, emotional upset, pregnancy, menstruation, and dental extraction. Some researchers have proposed to change the name of Bell's palsy to "herpetic facial paralysis" (45).

Predominantly, the current thought as to the most probable cause of Bell's palsy is activation of a latent HSV in the geniculate ganglion. There is no denying the repeated findings of the polymerase chain reaction and in situ hybridization studies. The HSV has been found in patients with Bell's palsy and in the latent phase in patients without Bell's palsy. However, the pathophysiology of Bell's palsy has been shown to involve not only cranial nerve VII, but also cranial nerves V, VIII, IX, and X in many cases (1,46-50). Research has also demonstrated involvement of the unaffected side with cranial nerve VII in more than 75% of cases (1,48).

Some authors suggest that facial nerve palsy may be merely the most apparent symptom of a more generalized polyneuritis. Activation of the latent HSV in the geniculate ganglion may be the reason that facial paralysis is the most pronounced sign of the polyneuritis. To affect the other cranial nerves and the contralateral side of the facial nerve, the lesion would need to be more proximal to the medulla where the cranial nerves have a common anatomical relationship. All of these cranial nerves have their origin within, or have neural pathways through, the medulla oblongata.

A three-directional misalignment of the atlas may compromise the size of the neural canal space (51,52) and has been postulated to jeopardize some functions of the medulla (53-55). Rosenberg et al (56) reported a case of cervical cord impingement, without a demonstrable misalignment observed with MRI, bringing on signs and symptoms of medulla compression.

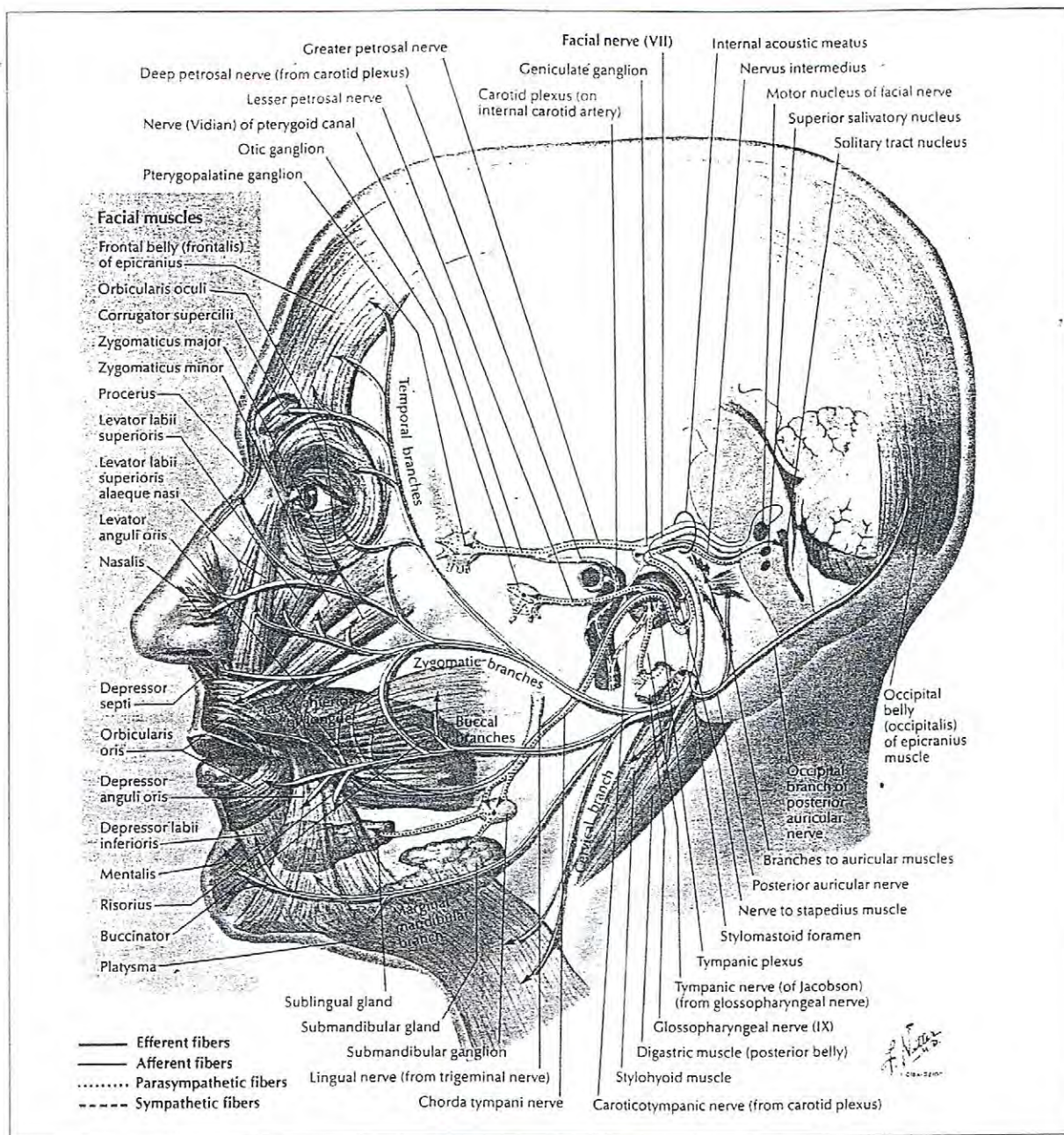


FIGURE 3. Illustration demonstrating the relationship between the upper cervical spine, the occiput, the facial nerve and the facial nerve ganglia. From Netter FH. Atlas of human anatomy. CIBA-GEIGY Corporation. Summit, NJ. 5th edition, 1992, plate 117. Reprinted with permission from Novartis Pharmaceutical Corporation, East Hanover, NJ.

Hack et al (57) found a well-organized connective tissue bridge passing from the rectus capitis posterior minor muscle through the atlanto-occipito junction and inserting onto the dura via the posterior atlanto-occipito (POA) membrane. The POA membrane was securely fixed to the dura by multitudinous, fine connective tissue fibers, and these two structures appear to function as a single entity. Hinson and Zeng (58) have observed through dissection that fibrous connective tissue serves to bridge the posterior longitudinal ligament and the dura from the top of

the odontoid process to the lower body of C2. The posterior longitudinal ligament was found to be firmly attached to the periosteum of the anterior canal at this level. Posterior connective tissue bridging to the posterior arch of C1 and to the lamina of C2 was evident as well. It appears through these findings that the spinal cord at the craniovertebral junction may be influenced by biomechanical aberrations in the upper cervical spine that are evident through protracto-view x-rays of the cervical spine (37,38,59).

Given the anatomical relationship shared by the upper cervical spine and the medulla oblongata (62-64), the upper cervical subluxation may conceivably compromise medullary function. Potentially, the condition of Bell's palsy may be precipitated by medulla compromise weakening the tissue's resistance to the polyneuritis.

A theory has been proposed that irritation of sympathetic nerves can elicit a condition of spasm within the vertebral artery, leading to a decrease in blood flow to the brain stem and brain. Terret (65) reported that misaligned vertebrae guiding arteries to the brain, presumably in the upper cervical spine, could create sufficient stress on the arteries to constrict the lumen. A decrease in blood circulation to vital regions in the medulla oblongata housing the nuclei of cranial nerves 5, 7, 8, 9, and 10 may disturb function, weakening resistance in a manner that could trigger the onset of Bell's palsy.

Patients 55 years of age and older or with hypertension have a prognosis that is not as favorable for full recovery. This age group, as well as hypertensive patients, presumably would have a greater tendency for vascular insufficiency.

It is not sufficient to conclude that HSV causes Bell's palsy when considering that HSV's activation appears to be one result of a cascade of effects that are part of a generalized polyneuritis. We assume that the pathogenesis of Bell's palsy originates in the medulla oblongata, because it is the only anatomical position that the cranial nerves, through their nuclei, have in common.

## CONCLUSION

The pathogenesis of Bell's palsy may be clouded by the fact that its most obvious clinical presentation is the immune system's response to the activated HSV. Consequently, if too much damage has not occurred, Bell's palsy will repair without intervention. Reduction of inflammation and edema within the internal auditory canal in the earlier stages, and remyelination of the 7th cranial nerve in the later stages, appears to be required to restore Bell's palsy patients to House-Brackmann Grade I. Lack of remyelination of the 7th cranial nerve within the internal auditory canal is the obstacle to Grade I recovery. The weakened resistance that allows the activation of the HSV is overshadowed clinically by the defense mechanism of the immune system.

The medullary centered pathogenesis of Bell's palsy is supported by circumstantial evidence. Common precipitating events of Bell's palsy are also factors that may either cause or exacerbate an existing upper cervical subluxation, with its neurological and vascular components. Both of the patients reported trauma within 10 to 14 days of onset of Bell's palsy, which may have caused or exacerbated an existing upper cervical subluxation. Perhaps the most compelling evidence for the cause-effect relationship of Bell's palsy and upper cervical subluxation is that Bell's palsy has been described as a generalized polyneuritis affecting other cranial nerves with a common origin in the medulla oblongata.

The first patient began care as House-Brackmann Grade VI

and achieved Grade I in eight months. Cases that do not completely resolve after six months may not reach Grade I. This patient's presentation and clinical history suggests that he may have been a candidate for a less favorable prognosis. However, neither of the cases presented underwent specialized examinations that would have given a quantitative indication of prognosis. The second patient went from Grade V to Grade I in eight weeks, faster than expected. Interpretation of the clinical progress documented in these two patients should be tempered with the understanding that most cases of Bell's palsy resolve with no intervention, even though significant recovery was recorded in both cases either immediately following or within a day of an upper cervical correction.

Traditional treatment for Bell's palsy is directed toward alleviating the cascading events of the immune response and not toward improving medullary and cranial nerve function. Corticosteroids have not been found to be successful when administered 24 hours or more after the onset of Bell's palsy. To validate upper cervical care as the treatment of choice for Bell's palsy, further studies should include prospective studies of upper cervical intervention for a larger number of patients, comparing recovery times of chiropractic-treated patients with recovery times for patients receiving no care or other types of treatments; or isolating cases through diagnostic examinations that have been determined to have a poor prognosis. Preadjustment and postadjustment examinations of nerve conduction velocity or EMG performed on Bell's palsy patients are available in the chiropractic clinics. These data gathered with pre- and post-adjustment examination for other cranial nerve functions could further substantiate the importance of upper cervical care for patients with Bell's palsy.

## REFERENCES

1. Ohye RG, Altenberger EA. Bell's palsy. *Am Fam Physician* 1989;40:159-66.
2. Merck Manual. 14th ed. Rahway (NJ): Merck, Sharp & Dohme; 1982:1377-8.
3. Kazemi B. A survey of idiopathic facial palsy (Bell's palsy) in southern Iran. *Pahlavi Med J* 1977;8:436-40.
4. Logan WP, Cushion AA. *Morbidity Statistics From General Practice*. Vol 1. London: General Register Office; 1958.
5. Katusic SK, Beard M, Wiederholt WC, Bergstralh EJ, Kurland LT. Incidence, clinical features, and prognosis in Bell's palsy, Rochester, Minnesota, 1968-1982. *Ann Neurol* 1986; 20:622-7.
6. Goncalves-Coelho TD, Pinheiro CN, Ferraz EV, Alonso-Neito JL. Clusters of Bell's palsy. *Arq Neuropsiquiatr* 1997;55:722-7.

7. De Diego JI, Prim MP, Madero R, Gavilan J. Seasonal patterns of idiopathic facial paralysis: a 16 year study. *Otolaryngol Head Neck Surg* 1999;120:269-71.
8. Ruckenstein MJ. Evaluating facial paralysis, expensive diagnostic tests are often unnecessary. *Postgrad Med* 1998;103:187-8, 191-2.
9. Shrode LW. Treatment of facial muscles affected by Bell's palsy with high-voltage electrical muscle stimulation. *J Manipulative Physiol Ther* 1993;16:347-52.
10. Wang Y, Zhang S, Xu H. A report of 164 cases of Bell's palsy. *Chung Hua Arh Pi Yen Hou Ko Tsa Chih* 1996;31:334-7.
11. Wolf SR. Idiopathic facial paralysis. *HNO* 1998;46:786-98.
12. Jori J, Szekely L, Kiss JG, Toth F. The prognostic value of facial nerve conduction velocity in patients with Bell's palsy. *Clin Otolaryngol* 1998;23:520-3.
13. Taki J, Yamamoto W, Nakajima K, Ichianagi K, Kato H. Prediction of prognosis in peripheral facial nerve paralysis using submandibular gland scintigraphy. *J Nucl Med* 1998;39:716-21.
14. Engstrom M, Abdsaleh S, Ahstrom H, Johansson L, Stalberg E. Serial gadolinium-enhanced magnetic resonance imaging and assessment of facial nerve function in Bell's palsy. *Otolaryngol Head Neck Surg* 1997;117:559-66.
15. Shafshak TS, Essa AY, Bakey FA. The possible contributing factors for the success of steroid therapy in Bell's palsy: a clinical and electrophysiological study. *J Laryngol Otol* 1994;108:940-3.
16. Litofsky NS, Megerian CA. Facial canal decompression leads to recovery of combined facial nerve paralysis and trigeminal sensory neuropathy: case report. *Surg Neurol* 1999;51:198-201.
17. Leuke CH, Johnson BW. Evaluation of a treatment plan for Bell's palsy: a case report. *Internat Chiropr Assoc Rev* 1988; Sep/Oct:46-7.
18. Frach JP, Ostenbauer PJ, Fuhr AW. Treatment of Bell's palsy by mechanical force, manually assisted chiropractic adjusting and high-voltage electrotherapy. *J Manipulative Physiol Ther* 1992;15:596-8.
19. Palmieri NF. Idiopathic facial paralysis: mechanism, diagnosis, and conservative chiropractic management. *Chiropr Technique* 1990;2:182-7.
20. Palmer DD. *The Chiropractic Adjuster*. Portland (OR): Portland Publishing Company; 1910.
21. Hart J. Skin temperature patterns of the posterior neck used in chiropractic analysis. *Chiropractic* 1991;7:46-8.
22. Duff SA. *Chiropractic clinical research, interpretation of spinal bilateral skin temperature differentials*. San Francisco: Paragon Printing; 1976.
23. Sherman L. *Neurocalometer - neurocalograph - neurotempometer research*. Eight B.J. Palmer Chiropractic Clinic cases. Davenport, IA: Palmer School of Chiropractic; 1951.
24. Palmer BJ. *Fight to Climb; Vol XXIV*. Davenport, IA: Palmer School of Chiropractic; 1950: 123-33.
25. *Neurocalometer Manual*. Davenport, IA: Palmer School of Chiropractic; 1934.
26. Kale MU. *Kale residency course - houston control skin temperature differential analysis*. Spartanburg, SC: Kale Technology and Research; 1989.
27. Wallace H, Wallace J, Resh R. *Advances in paraspinal thermographic analysis*. *Chiropr Res J* 1993;2(3):39-54.
28. Plaughner G, Lopes MA, Melch PE, Cremata EE. The inter- and intra-examiner reliability of a paraspinal skin temperature differential instrument. *J Manipulative Physiol Ther* 1991;14:361-67.
29. Stillwagon G, Stillwagon KL, Stillwagon BS, Dalesio DL. *Chiropractic thermography*. *Internat Chiropr Assoc Inter Rev Chiropr* 1992; Jan/Feb:8-13.
30. BenEliyahu DJ. *Infra-red thermal imaging of the vertebral subluxation complex*. *Internat Chiropr Assoc Inter Rev Chiropr* 1992; Jan/Feb:14-17.
31. Ebrall PS, Iggo A, Hobsen P, Farrant G. Preliminary report: the thermal characteristics of spinal levels identified as having differential temperature by contact thermocouple measurement (nervo scope). *Chiropr J Australia* 1994; 24:139-46.
32. Plaughner G. *Skin temperature assessment for neuromusculoskeletal abnormalities of the spinal column*. *J Manipulative Physiol Ther* 1992;15:365-81.
33. Palmer BJ. *Fight to Climb; Vol XXV*. Davenport, IA: Palmer School of Chiropractic; 1951:576-610.
34. Kale MU. *Certification residency course - Houston control upper cervical specific adjustment*. Spartanburg, SC: Kale Research and Technology; 1989.
35. Palmer BJ. *The subluxation specific - the adjustment specific; Vol XVIII*. Davenport, IA: Palmer School of Chiropractic, 1934: 82-86, 248-262, 359-371, 419-433, 456-468.
36. Palmer BJ. *The Subluxation Specific-The Adjustment Specific; Vol XVIII*. Davenport, IA: Palmer School of Chiropractic; 1934:202-6, 306-31.

37. Blair WG. Blair upper cervical spinographic research; primary and adaptive malformations; procedures for solving malformation problems; Blair principle of occipito-atlanto misalignment. [PhD Thesis]. Davenport IA: Palmer College of Chiropractic; 1968.
38. Blair WG. A synopsis of the Blair upper cervical spinographic research. *Sc Rev Chiropr (Internat Rev Chiropr: Sci Ed)* 1964;1:1-19
39. Palmer BJ. Chiropractic Clinical Controlled Research. Davenport, IA: Palmer School of Chiropractic; 1951:587.
40. Netter FH. Atlas of Human Anatomy. 5th ed. Summit, NJ: CIBA-GEIGY Corporation; 1992, plate 117.
41. Adour KK, Bell DN, Hilsinger RL Jr. Herpes simplex virus in idiopathic facial paralysis (Bell's palsy). *J Am-Med Assoc* 1975;233:527-30.
42. McGovern FH, Estevez J. Use of cromolyn sodium in Bell's palsy. In: Graham MD, House WF, eds. Disorders of the Facial Nerve: Anatomy, Diagnosis, and Management. New York: Raven; 1982:297-300.
43. Grose C, Henle W, Henle G, Feirino PM. Primary Epstein-Barr-virus infections in acute neurologic diseases. *N Engl J Med* 1975;292:392-5.
44. Schmutzhard E, Stanek G. *Borrelia burgdorferi*, a possible cause of Bell's palsy? *Clin Neurol Neurosurg* 1985;87:255-7.
45. Schirm J, Mulkens PS. Bell's palsy and herpes simplex virus. *APMIS* 1997;105:815-23.
46. Adour KK, Doty HE. Electronystagmographic comparison of acute idiopathic and herpes zoster facial paralysis. *Laryngoscope* 1973;83:2029-34.
47. Adour KK, Byl FM, Hilsinger RL Jr, Kahn ZM, Sheldon MI. The true nature of Bell's palsy: analysis of 1,000 consecutive patients. *Laryngoscope* 1978;88:787-801.
48. Safman BL. Bilateral pathology in Bell's palsy. *Arch Otolaryngol* 1971;93:55-7.
49. Chaco J. Subclinical peripheral nerve involvement in unilateral Bell's palsy. *Am J Physiol Med* 1973;52:195-7.
50. May M, Highes GB. Facial nerve disorders: update 1987. *Am J Otolaryngol* 1987;8:167-80.
51. Palmer BJ. Chiropractic Clinical Controlled Research; Vol XXV. Davenport, IA: Palmer School of Chiropractic, 1951:36-54.
52. Palmer BJ. The Great Divide. Davenport, IA: Palmer School of Chiropractic; 1961:26-34.
53. Kessinger R. Changes in pulmonary function associated with upper cervical specific chiropractic care. *J Vertebral Subluxation Res* 1997; 1(3):43-9.
54. Kessinger R, Boneva D. Changes in visual acuity in patients receiving upper cervical specific chiropractic care. *J Vertebral Subluxation Res* 1998; 2(1):43-9.
55. Crowe H, Kleinman T. Upper cervical influence on the reticular system. *The Upper Cervical Monograph* 1991; 5(1):12-14.
56. Rosenberg WS, Salame KS, Shumerick KV, Tew JM Jr. Compression of the upper cervical spinal cord causing symptoms of brainstem compromise. A case report. *Spine* 1998; 23:1497-500.
57. Hack GD, Koritzer RT, Robinson WL, Hallgren RC, Greenman PE. Anatomic relation between the rectus capitus posterior minor muscle and the dura mater. *Spine* 1995; 20:2484-6.
58. Hinson R, Zeng ZB. Epidural attachments in the upper cervical spine. *Chiropr Res J* 1999; 6:31-2.
59. Blair WG. A Synopsis of the Blair Upper Cervical Spinographic Research. Lubbock, TX: The Blair Society; 1968.
60. Rohen Y. Color Atlas of Anatomy: A Photographic Study of the Human Body. 2nd ed. New York: IGAKU-SHOIN; 1988.
61. Jacobs J. Shear's Manual of Human Dissection. 7th ed. New York: McGraw Hill; 1989:62.
62. Bland JH. Disorders of the Cervical Spine-Diagnosis and Medical Management. 2nd ed. Philadelphia: W.B. Saunders; 1994:47.
63. Haldeman S. Principles and Practice of Chiropractic. 2nd ed. Norwalk, CT: Appleton and Lange; 1992:47.
64. Schafer RC. Symptomatology and differential diagnosis-a conspectus of clinical semeiographies, Arlington, VA: Am Chiropr Assoc Press; 1994:554.
65. Terrett AGJ. Cerebral dysfunction: a theory to explain some of the effects of chiropractic therapy. *Chiropr Technique* 1993;5:168-73.