

CASE REPORT

Upper Cervical Chiropractic Management of a Multiple Sclerosis Patient: A Case Report

Erin L. Elster, D.C.

Abstract— This article reviews the upper cervical chiropractic management of a single patient with Multiple Sclerosis (MS). This 47-year-old female first experienced symptoms of MS at age 44, when she noticed cognitive problems and loss of bladder control. After viewing multiple lesions on MRI (MS plaques), her neurologist diagnosed her with MS. Two years later, she noticed additional symptoms of leg weakness and paresthesias in her arms and legs. Her symptoms progressively worsened without remission, so her neurologist categorized her as having chronic progressive MS and recommended drug therapy (Avonex). Upon initial examination of this patient, evidence of an upper cervical subluxation was found using precise upper cervical radiographs and paraspinous digital infrared imaging. The patient's medical history included one possible mechanism (a fall approximately ten years prior), which could have caused her upper cervical subluxation. The patient was placed on a specially designed knee-chest table for adjustment, which was delivered by hand to the first cervical vertebra according to radiographic findings. Monitoring of the patient's progress was through doctor's observation, patient's subjective description of symptoms, thermographic scans, neurologist's evaluation and MRI. The patient was managed with upper cervical chiropractic care for two years. After four months of upper cervical chiropractic care, all MS symptoms were absent. A follow-up MRI showed no new lesions as well as a reduction in intensity of the original lesions. After a year passed in which the patient remained asymptomatic, another follow-up MRI was performed. Once again, the MRI showed no new lesions and a continued reduction in intensity of the original lesions. Two years after upper cervical chiropractic care began, all MS symptoms remained absent. This case report revealed that this specific upper cervical procedure (thermal imaging, cervical radiographs, and knee-chest adjustments) was associated with a successful outcome for a patient with Multiple Sclerosis. Post MRI's, post thermographic scans, and the patient's neurologist's evaluation all suggested the intervention of upper cervical chiropractic care may have stimulated a reversal in the progression of Multiple Sclerosis.

Key Words: upper cervical spine, chiropractic, Multiple Sclerosis, vertebral subluxation, trauma, thermography, adjustment, manipulation

Introduction

Multiple Sclerosis (MS) is the foremost disabling neurological disease among adults between 20 and 50 years of age, afflicting 250,000 people in the United States. It strikes women twice as often as men and Caucasians more frequently than other ethnic groups. The occurrence of MS is greater in northern temperate zones.¹

The pathological process involved in MS, a demyelinating disease, is the loss of myelin sheaths surrounding axons in the

central nervous system (brain and spinal cord). Demyelination is thought to result either from damage to the oligodendrocytes (white matter cells) that produce the myelin or from a direct, immunologic (auto-immune) assault on the myelin itself.²

Common early manifestations of MS include paresthesias (numbness / tingling in extremities), optic neuritis (vision loss), mild sensory or motor symptoms in a limb, and cerebellar incoordination (balance loss). Although the most common course of the condition is a relapsing and remitting pattern over many years, the manifestation in each patient varies. In most cases, as the disease progresses, remissions become less complete. Some patients have only a few brief episodes of disability, whereas others have a relentless downhill course over months or weeks.

Erin L. Elster, D.C., Boulder, CO 80303

Although not all patients become disabled, the end stage often can include ataxia (inability to coordinate voluntary movement), incontinence, paraplegia, and mental dysfunction due to widespread cerebral and spinal cord demyelination.²

The MS diagnosis, primarily a clinical one, is usually rendered based on neurological history and examination. The diagnosis can be confirmed by specialized evaluation techniques including magnetic resonance imaging (MRI), evoked potentials, and cerebrospinal fluid (CSF) analysis, although none show findings pathognomonic for MS.³⁻⁵

Medical treatment for MS focuses upon the use of medications to regulate the severity of symptoms such as depression, pain, bladder impairment, and sexual dysfunction. Other drugs may accelerate recovery from acute exacerbations of MS or reduce the frequency of exacerbations, but they neither alter the long-term course of the condition nor reverse any existing MS symptoms.⁶

B.J. Palmer, D.C., reported management of Multiple Sclerosis patients with upper cervical chiropractic care as early as 1934.⁷⁻⁸ In his writings, Palmer listed improvement or correction of symptoms such as “spasticity, muscle cramps, muscle contracture, joint stiffness, fatigue, neuralgia, neuritis, loss of bladder control, paralysis, incoordination, trouble walking, numbness, pain, foot drop, inability to walk, and muscle weakness.” His chiropractic care included paraspinal thermal scanning using a neurocalometer (NCM), a cervical radiographic series to analyze upper cervical misalignment, and a specific upper cervical adjustment performed by hand.

While few of Palmer’s Research Clinic cases were published, Palmer described one case of Multiple Sclerosis in detail.⁸ The patient, a 38-year-old male, went to the Palmer Research Clinic in Davenport, Iowa in 1943, after a diagnosis of MS by the Mayo Clinic. At the time of admission into the Palmer Clinic, this subject was “...helpless; he could not feed nor take care of himself.” His medical history included a head / neck trauma at age 16 in which “...he fell ten feet off a building, landing on his head.” The fall rendered him unconscious for thirty minutes and he reported having a sore neck for several days. At the Palmer Clinic, upper cervical radiographs showed a misalignment of the atlas to the right. After upper cervical chiropractic care, the patient remarked, “I am happy to say that through chiropractic, I have been made almost well. Today, I have just a little numbness left in my hands. I have the full use of my hands, feet, and my whole body.”

During the past several decades, only three references were found linking chiropractic and Multiple Sclerosis: two single case studies and one five-patient report. Of the two single cases, one patient was adjusted with an instrument, while the other was managed with thoracolumbar manual chiropractic adjusting procedures.⁹⁻¹⁰ Both cases responded favorably. Of the five-patient report, five subjects were managed with upper cervical chiropractic care aided by cervical radiographs and thermal

imaging.¹¹ In all five cases, upper cervical subluxations were discovered and all patients showed improvement and/or correction of MS symptoms after the intervention of upper cervical chiropractic care.

The rationale for the use of upper cervical chiropractic care in this case was to correct the patient’s upper cervical subluxation that was discovered during cervical radiographic and thermal imaging procedures. Similar upper cervical subluxations were found in other patients (with conditions such as Parkinson’s disease, asthma, epilepsy, and fibromyalgia) who responded favorably to upper cervical chiropractic care (aided by cervical radiographs and thermal imaging).¹¹⁻¹⁷ This case report reviews the patient’s symptoms and objective findings before and after the intervention of upper cervical chiropractic care.

Case Report

This 46-year-old female first experienced MS symptoms at age 44. She noticed inability to formulate words when talking to her two-year-old daughter and difficulty processing complex thoughts or tasks at work. In addition, she had trouble with muscular control to begin and end urination. Her neurologist told her that loss of bladder control and cognition were symptoms of MS and ordered an MRI. After viewing white-matter lesions on MRI (MS plaques), her neurologist rendered an MS diagnosis. A cerebrospinal fluid analysis was also performed, which appeared normal. Two years after her diagnosis, she noticed additional symptoms of leg weakness that she described as a “rubbery feeling” and continuous, painful paresthesias (tingling and loss of sensation) in both arms and legs often awakening her at night. In

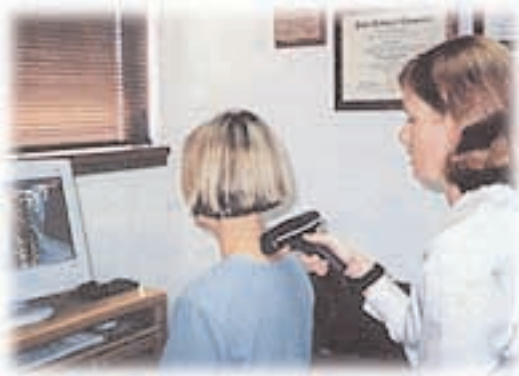

Figure 1: A patient being scanned with the Tytron C-3000 system

addition, the patient reported suffering from a stiff and achy neck for many years before noticing MS symptoms and demonstrated reduced and painful cervical extension. When questioned about her recollection of any past accidents, falls, head injuries, or whiplashes, the patient recalled a single fall over a decade prior to the onset of MS symptoms. Instead of the typical relapsing-remitting pattern, this patient’s neurologist considered her MS symptoms chronic and progressive, so he recommended drug therapy (Avonex) to slow the progression. Due to her concerns over long-term drug use, this subject chose to undergo upper cervical chiropractic care before beginning drug therapy.

The chiropractic care described below is based upon the original work performed by Palmer from the 1930’s through the 1950’s in the Palmer Research Clinic.⁸ The care was administered as taught by the International Upper Cervical Chiropractic Association (IUCCA) through their Applied Upper Cervical Biomechanics (AUCB) program.¹⁸

After the patient’s medical history was recorded, a paraspinal thermal analysis was performed with the Tytron C-3000 (Figure 1 - Titronics Research and Development) from the level of C7 to the occiput according to thermographic protocol.¹⁹⁻²¹ (Figure 2) Paraspinal digital infrared imaging measures cutaneous

infrared heat emission and is a form of thermography. Thermography is a neurophysiological diagnostic imaging procedure with over 6000 peer-reviewed and indexed papers in the past 20 years.²²⁻²⁴ Thermography has been established as a practical and sensitive test for spinal nerve root irritation, articular facet syndromes, peripheral nerve injuries, sympathetic pain syndromes, and the vertebral subluxation complex.²²⁻²⁴ Since the amount of blood passing through the skin is directly controlled by the sympathetic nervous system (through control of dilation or constriction of blood vessels), the temperature of any one area of the skin reflects the neurological control of that area. Normal or abnormal skin temperature then becomes an indicator of normal or abnormal neurological function. In blind studies comparing thermographic results to that of CAT scan, MRI, EMG, myelography, and surgery, thermography was shown to have a high degree of sensitivity (99.2%), specificity (up to 98%), predictive value, and reliability.²⁵⁻²⁷ Thermal imaging has been effective as a diagnostic tool for breast cancer, repetitive strain injuries, headaches, spinal problems, TMJ conditions, pain syndromes, arthritis, and vascular disorders, to name a few.²⁸⁻³⁷

Compared to established normal values for the cervical spine, the subject's paraspinal scans contained thermal asymmetries of 0.5°C (Figure 3). According to cervical thermographic guidelines, thermal asymmetries of 0.5°C or higher indicate abnormal autonomic regulation or neuropathophysiology.³⁸⁻⁴¹

In addition to revealing thermal asymmetries, the subject's scans displayed static thermal differences (Figure 4), thus, a thermal "pattern" was established. "Pattern analysis" of paraspinal temperatures was first developed by Palmer⁸ and paraspinal thermal analysis and pattern work are receiving increased attention in chiropractic research.⁴²⁻⁵³ Pattern work has been used recently in conjunction with upper cervical chiropractic care with Parkinson's disease, Multiple Sclerosis, fibromyalgia, epilepsy, and asthma.¹¹⁻¹⁷

Because upper cervical misalignments were suspected in this patient, a precision upper cervical radiographic series was per-

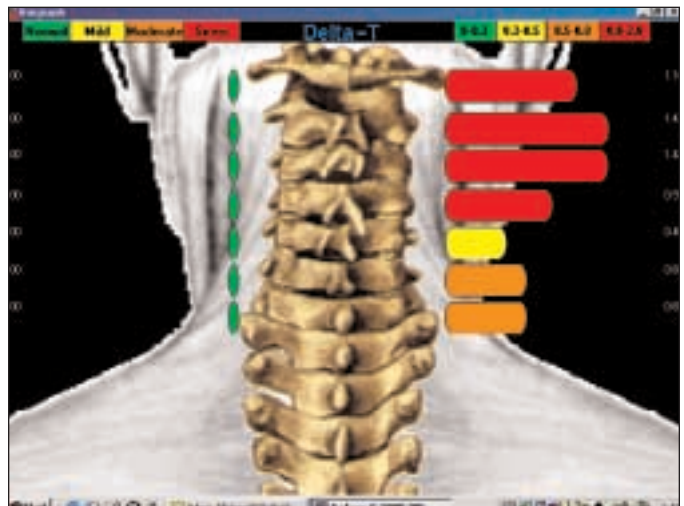
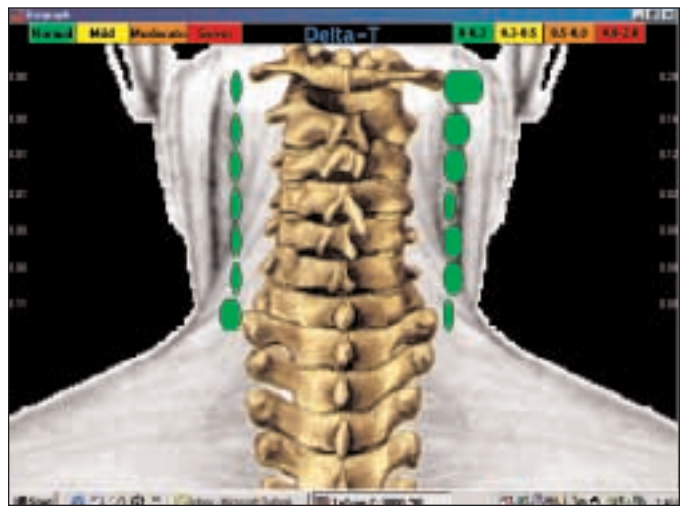
Figure 3

Example of cervical side to side thermal comparison. Normal scan (top), Thermal asymmetries at multiple levels (bottom).

Figure 2

Tytron C-3000 Thermographic Protocols

Environmental Controls —

- The temperature of your office should be held around 70 degrees Fahrenheit.
- No direct cooling or heating vent drafts should bear on the scanner.
- The scanner should not be placed in direct sunlight.
- Place the scanner holder away from the computer monitor and CPU.

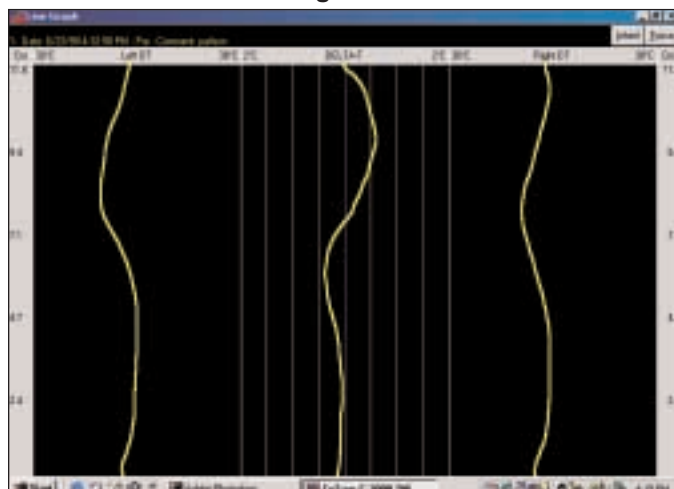
Patient Preparation —

- 15 minutes of office acclimation time must occur before scanning the patient.
- The patient's spine must be disrobed or loosely gowned during acclimation.
- The patient must remain free from direct heating or cooling drafts.
- No direct sunlight should bear on the patient while in the office.
- No EMS, TENS, US, hot or cold packs, or acupuncture before scanning.
- The patient must be free from sunburn.

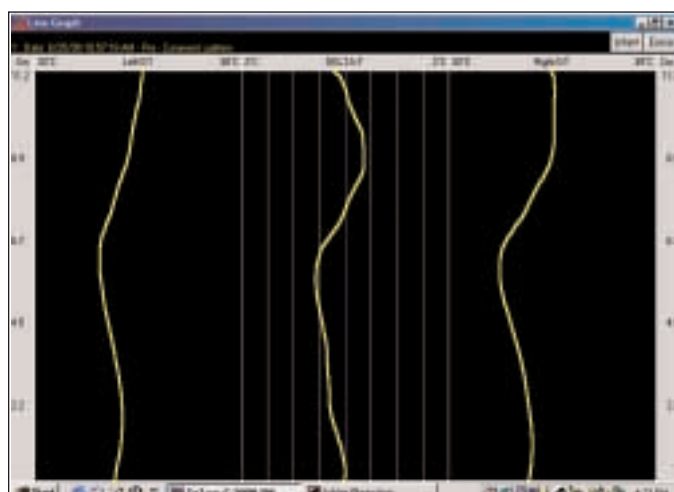
formed.⁵⁴ The x-ray equipment included a laser-aligned frame (American X-ray Corporation) to eliminate image distortion. To maintain postural integrity, this subject was placed in a positioning chair using head clamps. In addition, the patient was aligned to the central ray using a laser (Titronics Research and Development) mounted on the x-ray tube. The four views (lateral, anterior-posterior, anterior-posterior open mouth, and base posterior) enabled examination of the upper cervical spine in three dimensions: sagittal, coronal, and transverse. Analysis of the four views was directed towards the osseous structures (foramen magnum, occipital condyles, atlas, and axis) that are intimately associated with the neural axis. Laterality and rotation of atlas and axis were measured according to each vertebra's deviation from the neural axis (Figure 5).⁵⁵ Right laterality of atlas and axis and right posterior rotation of atlas were found (Figure 6).

The two criteria used to determine subluxation in this case were thermal asymmetry (measured by thermal imaging) and vertebral misalignment (measured by cervical radiographs). Because both criteria (0.5°C thermal asymmetry and right laterality and right posterior rotation of atlas) were met, a care plan

Figure 4



Scan 1



Scan 2

Establishment of a static pattern. The center graph represents the temperature differential (Delta-T) or difference in temperature between either side of the spine. The right and left side graphs denote the direct temperatures (DT) or actual surface temperatures over the paraspinal skin. Note how the line graphs follow a similar thermographic pattern.

was discussed with the patient. In addition, it was recommended that the subject continue consulting with her neurologist. After the patient consented, upper cervical chiropractic care began with an adjustment to correct the right laterality and posterior rotation of atlas. To administer the adjustment, the patient was placed on a knee-chest table with her head turned to the right (Figure 7). The knee-chest posture was chosen because of the accessibility of the anatomy to be corrected. Using the right posterior arch of atlas as the contact point, an adjusting force was introduced by hand.⁵⁵ The adjustment's force (force = mass X acceleration) was generated using body drop (mass) and a toggle thrust (acceleration).

Then, the patient was placed in a post-adjustment recuperation suite for fifteen minutes as per thermographic protocol (Figure 2).¹⁹⁻²¹ After the recuperation period, a post-adjustment thermal scan was performed. The post-adjustment scan revealed a thermal difference of only 0.1 °C, which was considered nor-

mal according to established cervical thermographic guidelines (compared to the pre-adjustment differential of 0.5 °C). Therefore, resolution of the patient's presenting thermal asymmetry (elimination of the thermal "pattern") was achieved (Figures 8 & 9).

All subsequent office visits began with a thermal scan. An adjustment was administered only when the patient's presenting thermal asymmetry ("pattern") returned. If an adjustment was given, a second scan was performed after a fifteen-minute recuperation period to determine whether restoration of normal thermal symmetry had occurred. This subject's office visits occurred two times per week for the first four weeks of care. After the initial adjustment, two other adjustments were administered during the first month. Visits were reduced to once per week for the second month of care. Adjustments were necessary on two of the four visits. By the third month of care, thermal asymmetry was rarely present, so visits were reduced to once per month.

Within the first week of upper cervical care, this subject reported improved bladder control (resumption of muscular control to begin and end urination) and a decrease in numbness,

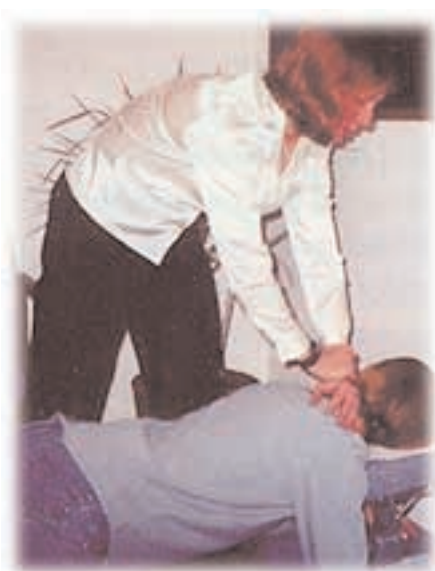

Figure 7: Example of patient positioning for knee-chest adjustment

Figure 5 (see Figure 6, page 26)

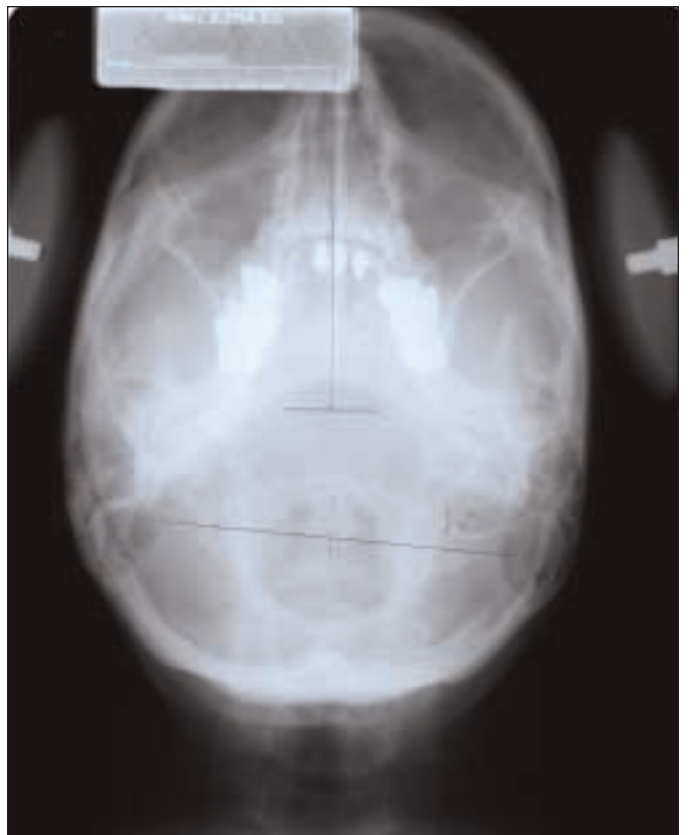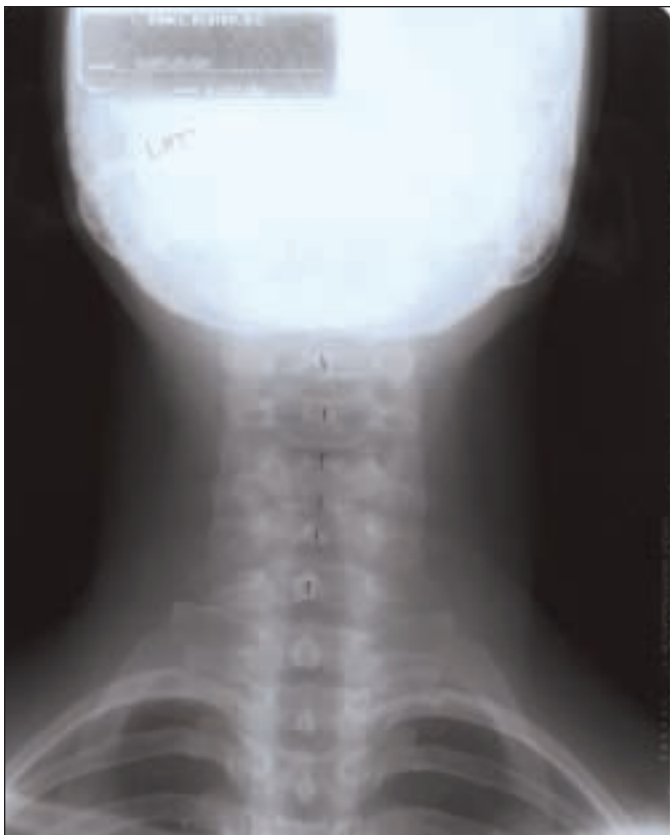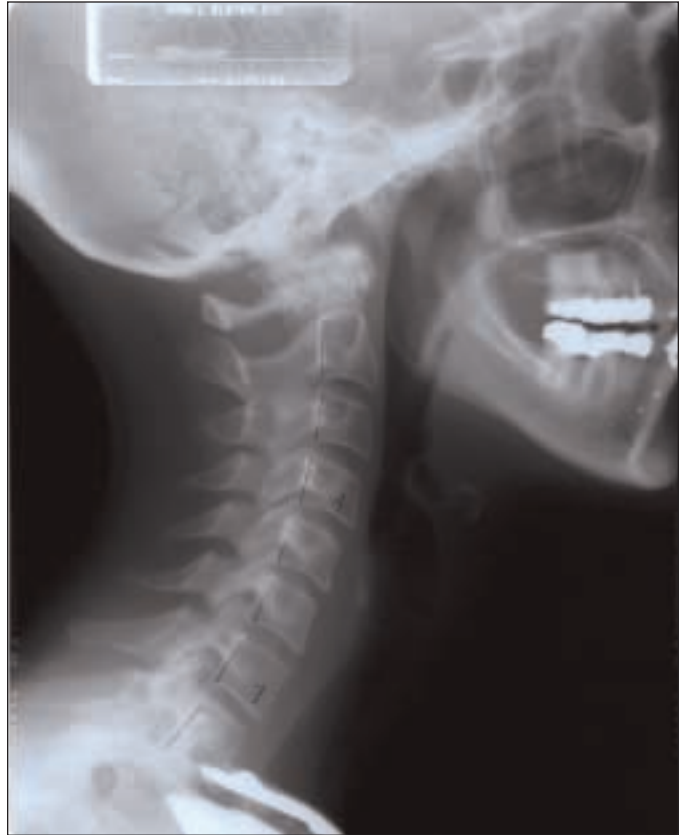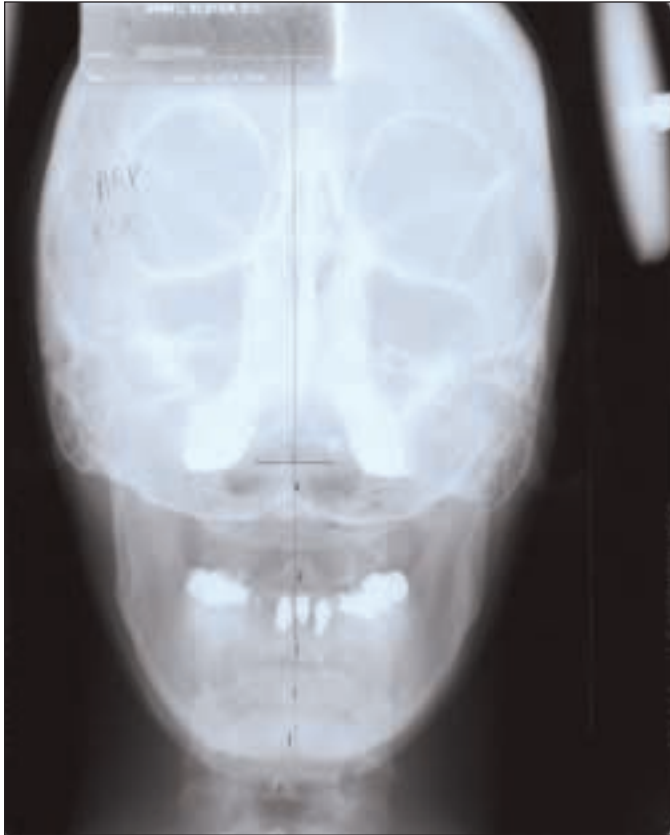To determine laterality from the anterior-posterior open mouth film, a horizontal line was drawn across the upper one-third of the foramen magnum's arch from cortex to cortex. The foramen magnum line was bisected with a vertical median line from the film's top to bottom.

Using a compass' point on the vertical line, arcs were drawn through each lateral mass of atlas. Using the left lateral mass as the constant, if the right lateral mass stayed within the right arc, the atlas was listed as "left." If the right lateral mass extended beyond the right arc, the atlas was listed as "right."

Axis laterality was determined by locating the position of the odontoid and spinous processes according to the vertical median line. To determine atlas rotation from the base-posterior film, an atlas plane line was drawn through the transverse foramen of atlas. The next line was drawn horizontally across the cortical borders of the clivus (ossification center of the skull) from cortex to cortex. This skull line was bisected.

Atlas rotation was determined by using a protractor to measure the difference between the bisected skull line and the atlas plane line. An angle less than 90 degrees represented "anteriority". An angle more than 90 degrees represented "posteriority."

Figure 6



(See Figure 5, page 25, for explanation on how lines of mensuration were drawn.)

tingling, and pain in her left leg and right hand. One month later, her leg strength returned (“rubbery feeling” was absent) and numbness was noted only in her left hand. In addition, she reported experiencing normal cognitive ability in that she could formulate words and process complex thoughts. After two months of care, bladder control, sensation, and strength in her extremities returned to normal. After four months of upper cervical care, this subject reported the absence of all MS symptoms. A follow-up MRI five months after the first showed no new lesions as well as a reduction in intensity of the original lesions.

During the subsequent year, this patient was examined once per month with paraspinial digital infrared imaging. During three of the twelve visits, thermal asymmetry (“pattern”) was present so an adjustment was administered. No MS symptoms reoccurred during the year. A third MRI performed ten months after the second once again showed no new lesions and continued reduction in intensity of the original lesions. The patient’s neurologist considered her case stable, no longer recommended drug treatment, and suggested she be reexamined once per year with MRI. Two years after the first adjustment was administered, the patient remained asymptomatic. During the two-years of upper cervical care, no other intervention was reported that could have provided an alternative explanation for the dramatic improvement of the patient’s condition.

Discussion

An important aspect of this patient’s medical history was her recollection of a fall, which could have caused her upper cervical subluxation. The body of medical literature detailing a possible trauma-induced etiology for MS, or at least a contribution, is substantial.⁵⁶⁻⁶⁶ Trauma also has been implicated as a cause of other similar degenerative neurological disorders such as Parkinson’s disease and Amyotrophic Lateral Sclerosis.⁶²⁻⁶⁴ When Parkinson’s disease patients were examined with thermal imaging and cervical radiographs, they too showed evidence of upper cervical subluxations and responded favorably to upper cervical chiropractic care.¹⁶⁻¹⁷

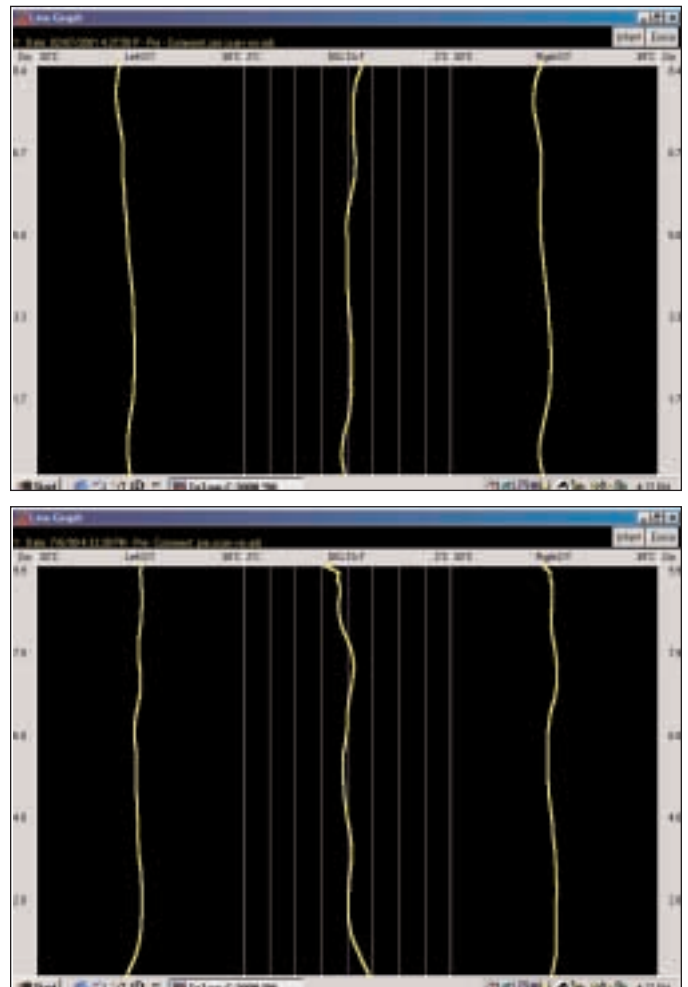
Recent research has suggested that an alteration of the blood-brain barrier (BBB) is an obligatory step in the pathogenesis of MS lesions.⁵⁸⁻⁶⁰ Evidence supports that trauma (in particular mild concussive injury to the head, neck or upper back) impinges on the brain and spinal cord, and may result in an increase in BBB permeability.⁵⁸⁻⁶⁰ While medical research shows that trauma may lead to MS, no mechanism has been defined. It is the author’s hypothesis that the missing link may be the injury to the upper cervical spine.

While various theories have been proposed to explain the effects of chiropractic adjustments, a combination of several theories seems most likely to explain the profound changes seen in this MS patient due to upper cervical chiropractic care. After a spinal injury, central nervous system (CNS) facilitation can occur from an increase in afferent signals to the spinal cord and/or brain coming from articular mechanoreceptors.⁷⁰⁻⁷⁴ The upper cervical spine is uniquely at risk for this problem because it possesses inherently poor biomechanical stability (lacks intervertebral discs and vertical zygapophyseal joints) along with the greatest concentration of spinal mechanoreceptors.

Hyperafferent activation (through CNS facilitation) of the sympathetic vasomotor center in the brainstem and/or the superior cervical ganglion may lead to changes in cerebral blood flow, including ischemia.⁷⁵⁻⁸¹ Because of the close association between the nervous and immune systems (the immune system is commonly classified as the neuroimmune system),⁸²⁻⁸³ upper cervical injuries affecting sympathetic function consequently may cause a cascade of non-favorable immune responses.⁸⁴⁻⁸⁷ Among these are uncoordinated immune tissue responses (auto-immune responses) and the release of cortisol, which ultimately can result in decreased immune function.

It is possible that this MS patient sustained an injury to her upper cervical spine (visualized on cervical radiographs) during the spinal trauma she experienced. It is also possible that due to the injury, through the mechanisms described previously, sympathetic malfunction occurred (measured by paraspinial digital infrared imaging), possibly causing decreases in cerebral blood flow. Consequently, because the nervous and immune systems are so closely intertwined, it is possible that CNS facilitation and cerebral ischemia could have stimulated an auto-immune response such as myelin destruction or an increased permeability of the blood-brain barrier. According to the symptomatic improvement and the objective changes via MRI and thermogra-

Figure 8



These graphs demonstrate when the patient was not “in pattern” and no adjustment was given on those days.

phy in the patient discussed in this report, it seems that adjustment of the upper cervical subluxation had a beneficial effect possibly stopping and perhaps even reversing the MS. Similar results occurred in five other MS patients whose upper cervical subluxations were corrected with upper cervical chiropractic care.¹¹

Conclusion

This case report details the medical history and symptoms of a 46-year-old female suffering from Multiple Sclerosis; the two-year intervention of upper cervical chiropractic care; and the patient's symptomatic response. At this patient's initial evaluation, evidence of an upper cervical subluxation was found using paraspinal digital infrared imaging and upper cervical radiographs. The upper cervical subluxation was corrected by performing a specific adjustment by hand to the first cervical vertebra according to radiographic findings. The patient's medical history included one possible mechanism (a fall) for her upper cervical subluxation. After four months of upper cervical chiropractic care, all previous symptoms of MS were absent. A follow-up MRI showed no new lesions as well as a reduction in intensity of the original lesions. After a year passed in which the patient remained asymptomatic, another follow-up MRI was performed. Once again, the MRI showed no new lesions and a continued reduction in intensity of the original lesions. Two years after upper cervical chiropractic care began, all MS symptoms remained absent. Further investigation into upper cervical trauma and resulting neuropathophysiology as a possible etiology or contributing factor to Multiple Sclerosis should be pursued. To confirm that this positive outcome could be replicated in additional patients, it is also recommended that a larger study be performed because few conclusions can be drawn from a small number of cases.

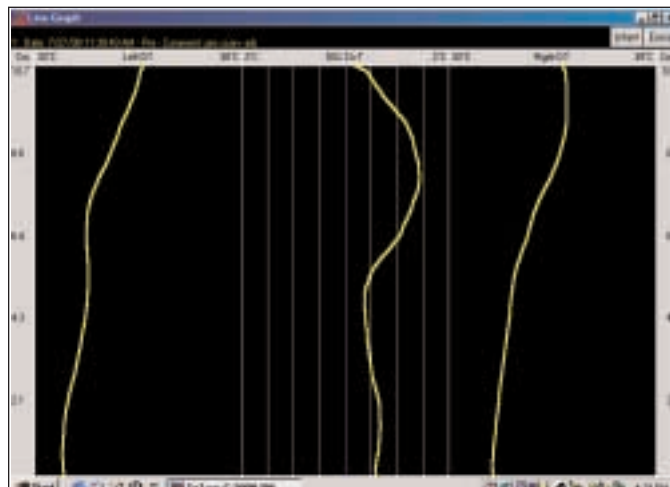
Acknowledgements

The author gratefully acknowledges Drs. William Amalu and Louis Tiscareno of the International Upper Cervical Chiropractic Association (IUCCA) for their Applied Upper Cervical Biomechanics (AUCB) Course and the Titronics Corporation for the Tytron C-3000 Paraspinal Digital Thermal scanner.

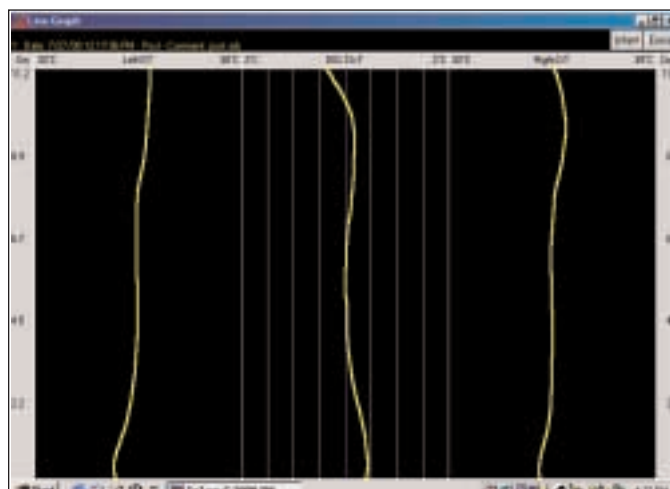
References

1. Facts about MS. www.mscenter.org. Denver, Colorado: Center for Neurological Diseases, Rocky Mountain Multiple Sclerosis Center. 1999.
2. Guyton A. Textbook of Medical Physiology, 8th Ed. Philadelphia: W.B. Saunders Co., 1991.
3. Hallpike J. Multiple sclerosis-making the diagnosis. Aust Fam Physician 1992 Oct; 21 (10): 1407-10.
4. Miller A. Diagnosis of multiple sclerosis. Semin Neurol 1998; 18(3): 309-16.
5. David P, Ristori GP, Elia M. Multiple sclerosis. Magnetic resonance imaging, evoked potentials, cerebrospinal fluid analysis. Acta Neurol 1990 Jun; 12(3): 200-6.
6. Betaseron Information. www.betaseron.com. The Betaseron MS Resource Center, Berlex Laboratories. 1993.
7. Palmer, BJ. The Subluxation Specific The Adjustment Specific. Davenport, Iowa: Palmer School of Chiropractic, 1934: 862-70.
8. Palmer, BJ. Chiropractic Clinical Controlled Research. Davenport, Iowa: Palmer School of Chiropractic, 1951: 417-32.
9. Kirby S. A case study: the effects of chiropractic on multiple sclerosis. CRJ 1994; 3(1): 7-12.

Figure 9



Example of pre-adjustment pattern.



Example of post adjustment scan with loss of pattern.

10. Stude D, Mick T. Clinical presentation of a patient with multiple sclerosis and response to manual chiropractic adjustive therapies. JMPT 1993 Nov; 16(9): 595-600.
11. Elster E. Upper cervical protocol for five multiple sclerosis patients. Today's Chiropractic 2000 Nov; 29(6): 76-92.
12. Amalu W. Chiropractic management of 47 asthma cases. Today's Chiropractic 2000 Nov; 29(6): 94-101.
13. Amalu, W. Autism, asthma, irritable bowel syndrome, strabismus and illness susceptibility: a case study in chiropractic management. Today's Chiropractic 1998 Sept; 27(5): 32-47.
14. Amalu, W. Cortical blindness, cerebral palsy, epilepsy, and recurring otitis media: a case study in chiropractic management. Today's Chiropractic 1998 May; 27(3): 16-25.
15. Amalu, W. Upper cervical management of primary fibromyalgia and chronic fatigue syndrome cases. Today's Chiropractic 2000 May; 29(3): 76-86.
16. Elster E. Upper cervical management of ten Parkinson's disease patients. Today's Chiropractic 2000 July; 29(4): 36-48.
17. Elster E. Upper cervical chiropractic management of a patient with Parkinson's disease: a case report. J Manipulative Physiol Ther 2000 Oct; 23(8) 573-7.
18. Applied Upper Cervical Biomechanics program. www.pacificchiro.com. Redwood City, California: International Upper Cervical Chiropractic Association, 1993.
19. International Thermographic Society. Thermography protocols. In: Amalu W, Tiscareno L. Clinical neurophysiology and paraspinal thermography: module 2-applied upper cervical biomechanics course. Redwood City, Calif: International Upper Cervical Chiropractic Association; 1993. p.67-70.

20. American Academy of Thermology. Thermography Protocols. In: Amalu W, Tiscareno L. Clinical neurophysiology and paraspinal thermography: module 2-applied upper cervical biomechanics course. Redwood City, Calif: International Upper Cervical Chiropractic Association; 1993. p.67-70.
21. American Academy of Medical Infrared Imaging. Thermography Protocols. In: Amalu W, Tiscareno L. Clinical neurophysiology and paraspinal thermography: module 2-applied upper cervical biomechanics course. Redwood City, Calif: International Upper Cervical Chiropractic Association; 1993. p.67-70.
22. Amalu W, Tiscareno L, et al. Clinical neurophysiology and paraspinal thermography: module 2- Applied Upper Cervical Biomechanics Course. Redwood City, Calif: International Upper Cervical Chiropractic Association, 1993. p.62-70.
23. Amalu W, Tiscareno L. Objective analysis of neuropathophysiology, Part 1. Today's Chiropractic 1996 May; 25(3): 90-6.
24. Amalu W, Tiscareno L. Objective analysis of neuropathophysiology, Part 2. Today's Chiropractic 1996 July; 25(4): 62-66.
25. Goldberg G. Thermography and magnetic resonance imaging correlated in 35 cases. Thermology 1986; 1: 207-11.
26. Thomas D, Cullum D, Siahamis G. Infrared thermographic imaging, magnetic resonance imaging, CT scan and myelography in low back pain. Br J Rheumatol 1990; 29: 268-73.
27. Weinstein SA, Weinstein G. A clinical comparison of cervical thermography with EMG, CT scanning, myelography and surgical procedures in 500 patients. Proceedings of the 1st annual meeting of the Academy of Neuromuscular Thermography; 1985 May. Postgrad Med 1986; Special ed: 44-6.
28. Gros C, Gautherie M. Breast thermography and cancer risk prediction. Cancer 1980; 45(1): 51-56.
29. Diakow P. Thermographic imaging of myofascial trigger points. JMPT 1988; 11(2): 114-17.
30. Drummond PD, Lance JW. Thermographic changes in cluster headaches. Neurology 1984; 34:1292-98.
31. Hendler N, Uematsu S. Thermographic validation of physical complaints in psychogenic pain patients. Psychosomatics 1982;23.
32. Zellner J, Bandler H. Thermographic assessment of carpal tunnel syndrome. J Bone Joint Surg 1986; 10: 558.
33. Weinstein SA, Weinstein G. A protocol for the identification of temporomandibular joint disorder by standardized computerized electronic thermography. Clin J Pain 1987; 3: 107-12.
34. Sionni, IH. Thermography in suspected deep venous thrombosis of lower leg. Europ J Radiol May 1985; 281-84.
35. Ecker A. Reflex sympathetic dystrophy thermography in diagnosis. Psychiatric Annals 1984; 14(11): 787-93.
36. Swerdlow B, Dieter JN. The persistent migraine cold patch and the fixed facial thermogram. Thermology 1986; 2:1620.
37. Wood EH. Thermography in the diagnosis of cerebrovascular disease. Radiology 1965; 85: 270-83.
38. Uematsu, E, et al. Quantification of thermal asymmetry, part 1: normal values and reproducibility. J Neurosurg 1988; 69: 552-555.
39. Feldman F, Nicoloff E. Normal thermographic standards in the cervical spine and upper extremities. Skeletal Radiol 1984; 12: 235-249.
40. Clark RP. Human skin temperatures and its relevance in physiology and clinical assessment. In: Francis E, Ring J, Phillips B, et al. Recent advances in medical thermology. New York: Plenum Press, 1984, 5-15.
41. Uematsu S. Symmetry of skin temperature comparing one side of the body to the other. Thermology 1985; 1:4-7.
42. Hart, J.F., Boone, W.R. Pattern Analysis of Paraspinal Temperatures: A Descriptive Report. Journal of Vertebral Subluxation Research, Vol. 3, No. 4, 2000.
43. Miller JL. Skin temperature instrumentation. International Review of Chiropractic. April 1967, pp. 39-41.
44. Kent C. Paraspinal skin temperature differentials and vertebral subluxation. The Chiropractic Journal. September 1999.
45. Schram SB, Hosek RS, Owens ES. Computerized paraspinal skin surface temperature scanning: A technical report. J Manip Physiol Ther 1982; 5(3): 117-122.
46. Ebrall PS, Iggo A, Hobson P, Farrant G. Preliminary report: The thermal characteristics of spinal levels identified as having differential temperature by contact thermocouple measurement (Nervo Scope). Chiropr J of Australia 1994; 24(4):139-143.
47. Stewart MS, Riffle DW, Boone WR. Computer-aided pattern analysis of temperature differentials. J Manip Physiol Ther 1989;12(5):345-352.
48. Brand NE, Gizoni CM. Moire contourgraphy and infrared thermography: changes resulting from chiropractic adjustments. J Manip Physiol Ther 1982; 5(3): 113-119.
49. DeBoer K, et al. Inter- and intra-examiner reliability study of paraspinal infrared temperature measurements in normal students. Research Forum 1985; 2(1):4-12.
50. Plaughter G. Skin temperature assessment for neuromusculoskeletal abnormalities of the spinal column. J Manip Physiol Ther 1992;15(6):368.
51. Salminen, B.J., Misra, T. Inter- and Intra-examiner Reliability of the TyTron C-3000. Abstracts of the Eighth Annual Vertebral Subluxation Research Conference Sponsored by Sherman College of Straight Chiropractic. Journal of Vertebral Subluxation Research, Vol 4, No. 1, 2000
52. Senzon, S.A. The Theory of Chiropractic Pattern Analysis Based on the New Biology. Abstracts of the Eighth Annual Vertebral Subluxation Research Conference Sponsored by Sherman College of Straight Chiropractic. Journal of Vertebral Subluxation Research, Vol 4, No. 1, 2000
53. Hart, J.F. Analyzing the neurological interference component of the vertebral subluxation with the use of pattern analysis: A Case Report. Abstracts of Association of Chiropractic Colleges Eighth Annual Conference. The Journal of Chiropractic Education, Vol. 15, No. 1, 2001.
54. Amalu W, Tiscareno L, et al. Precision Radiology: Module 1 and 5- Applied Upper Cervical Biomechanics Course. Redwood City, Calif: International Upper Cervical Chiropractic Association, 1993. p.65-84.
55. Amalu W, Tiscareno L, et al. Precision Multivector Adjusting: Modules 3 and 7- Applied Upper Cervical Biomechanics Course. Redwood City, Calif: International Upper Cervical Chiropractic Association, 1993. P. 64-73.
56. Christie B. Multiple sclerosis linked with trauma in court case. BMJ (BMJ) 1996 Nov 16; 313 (7067): 1228.
57. Christie B. Appeal overturns link between multiple sclerosis and whiplash. BMJ (BMJ) 1998 Mar; 316: 797.
58. Poser CM. Trauma to the central nervous system may result in formation or enlargement of multiple sclerosis plaques. Arch Neurol 2000 Jul; 57(5): 1074-7.
59. Poser CM. The role of trauma in the pathogenesis of multiple sclerosis: a review. Clin Neurol Neurosurg 1994 May; 96(2): 103-10.
60. Poser CM. The pathogenesis of multiple sclerosis. Additional considerations. J Neurol Sci 1993 Apr; 115 Suppl: S3-15.
61. Martinelli V. Trauma, stress, and multiple sclerosis. Neurol Sci 2000; 21(4 Suppl 2): S849-52.
62. Casetta I, Granieri E. Prognosis of multiple sclerosis: environmental factors. Neurol Sci 2000; 21 (4 Suppl 2): S839-42.
63. Rudez J, Antonelli L, Materljan E. Injuries in the etiopathogenesis of multiple sclerosis. Lijec Vjesn 1998 Jan-Feb; 120(1-2): 24-7.
64. Gusev E, Boiko A, Lauer K. Environmental risk factors in MS: a case-control study in Moscow. Acta Neurol Scand 1996 Dec; 94(6): 386-94.
65. Morrison W, Nelson J. Environmental triggers in Multiple Sclerosis. Fact of fallacy? Axone 1994 Sep; 16(1): 23-6.
66. Traynelis VC, Hitchon PW, Yuh WT. Magnetic resonance imaging and posttraumatic Lhermitte's Sign. J Spinal Disord 1990 Dec; 3(4): 376-9.
67. Goetz CG, Pappert EJ. Trauma and movement disorders. Neurol Clin (NEU) 1992 Nov; (4): 907-19.
68. Factor SA, Sanchez-Ramos J, Weiner WJ. Trauma as an etiology of parkinsonism: a historical review of the concept. Mov Disord (NIA) 1988; 3(1): 30-6.
69. Gallagher JP, Sanders M. Trauma and amyotrophic lateral sclerosis: a report of 78 patients. Acta Neurol Scand 1987 Feb; 75(2): 145-50.
70. Gardner E. Pathways to the cerebral cortex for nerve impulses from joints. Acta Anat 1969; 56: 203-16.
71. Wyke B. The neurology of joints: a review of general principles. Clin Rheum Dis 1981; 7: 223-39.
72. Coote J. Somatic sources of afferent input as factors in aberrant autonomic, sensory, and motor function. In: Korr I. The neurobiological mechanisms in manipulative therapy. New York: Plenum, 1978: 91-127.
73. Denslow J, Korr I. Quantitative studies of chronic facilitation in human motorneuron pools. Am J Physiol 1987; 150: 229-38.
74. Korr I. Proprioceptors and the behavior of lesioned segments. In: Stark E. Osteopathic medicine. Acton, Mass: Publication Sciences Group, 1975: 183-99.

75. Heiss W, Hayakawa T. Cortical neuronal function during ischemia. *Arch Neurol* 1976; 33: 813-20.
76. Astrup J, Siesjo B. Thresholds in cerebral ischemia- the ischemic penumbra. *Stroke* 1981; 12: 723-25.
77. Roski R, Spetzler R. Reversal of seven-year-old visual field defect with extracranial-intracranial anastomosis. *Surg Neurol* 1978; 10: 267-68.
78. Mathew R, Meyer J. Cerebral blood flow in depression. *Lancet* 1980; 1(818): 1308.
79. Mathew R, Weinmann M. Personality and regional cerebral blood flow. *Br J Psychiatry* 1984; 144: 529-32.
80. Jacques S, Garner J. Reversal of aphasia with superficial temporal artery anastomosis. *Surg Neurol* 1976; 5: 143-45.
81. Lee M, Ausman J. Superficial temporal to middle cerebral artery anastomosis: clinical outcome in patients with ischemia of infarction in internal carotid artery distribution. *Arch Neurol* 1979; 36: 1-4.
82. Anisman H, Baines MG, Berczi I. Neuroimmune mechanisms in health and disease: 1. Health. *CMAJ* 1996 Oct 1; 155(7): 867-74.
83. Anisman H, Baines MG, Berczi I. Neuroimmune mechanisms in health and disease: 2. Disease. *CMAJ* 1996 Oct 15; 155(8): 1075-82.
84. Elenkov IJ, Wilder RL, Chrousos GP. The sympathetic nerve- an integrative interface between two supersystems: the brain and the immune system. *Pharmacol Rev* 2000 Dec; 52(4): 595-638.
85. Wick G. Immunoendocrine communication via the hypothalamus-pituitary-adrenal axis in autoimmune diseases. *Endocrine reviews* 1993 Oct; 14: 539-63.
86. Black P. Immune system- central nervous system interaction: effect and immunomodulatory consequences of immune system mediators on the brain. *Antimicrobial Agents and Chemotherapy* 1994 Jan; 38: 7-12.
87. Ader R, Cohen N, Felten D. Psychoneuroimmunology: interactions between the nervous system and the immune system. *Lancet* 1996 Jan; 345: 99-103.